

HYPERACUTE EXTRADURAL HEMATOMA MIMICKING ACUTE SUBDURAL HEMATOMA

Amit Agrawal

Department of Neurosurgery, B.P Koirala Institute of Health Sciences, Dharan, Nepal

Correspondence to: Dr. Agrawal, Assistant Professor in Neurosurgery, Department of Surgery, B.P. Koirala Institute of Health Sciences, Dharan, Nepal. Tel: 977-25-525555, ext 2047; Fax: 977-25-520251. Email: dramitagrawal@gmail.com

Pak J Neurol Sci 2008; 3(1):12-13

ABSTRACT

On CT scan a rapidly accumulating extradural hematoma can be crescentic in shape. We report a case of hyperacute extradural hematoma mimicking acute subdural hematoma on CT scan. Detailed and careful evaluation of images is necessary to make a correct diagnosis in these cases. Whether it is acute subdural hematoma or extradural hematoma, it should not delay the surgical management as early intervention will result in good recovery and any delay can be fatal.

Rapidly accumulating extradural hematoma can be crescent-shaped and can mimic acute subdural hematoma. We report a case of hyperacute extradural hematoma mimicking acute subdural hematoma and describe the relevant radiological findings favoring pre-operative diagnosis of extradural hematoma.

CASE REPORT

A 16-year old child presented to us 5 hours after a fall from a tree. He was in altered sensorium since then. He had 2-3 episodes of vomiting and there was a history of nasal bleed. There was no history of seizures. His general and systemic examinations were within normal limits. Neurologically he was in altered sensorium (Glasgow Coma Score E3 V5 M3) and pupils were bilaterally equal and normally reactive to light. There was no paucity of movements. On local examination he had an extensive subgaleal hematoma in the right fronto-temporal region with right black eye. Urgent CT scan (approximately 6 hours after injury) was performed and it showed a crescent-shaped hyperdense collection and an area of hypodensity in the right fronto-temporo-parietal region (9.6 x 8 x 1.4 cm), with associated mass effect and a midline shift of 0.7 mm (Figure 1). Specks of pneumocephalus were seen in the blood clot (Figure 1). A speck of contusion in the medial basifrontal region (Figure 1) and fracture of the right frontal bone extending into the

sphenoid and temporal bone were also noted (Figures 2 & 3).

A diagnosis of hyperacute extradural hematoma was made. The patient underwent emergency right fronto-temporo-parietal craniotomy and evacuation of extradural hematoma. During surgery, there was extensive subgaleal hematoma. There was linear fracture of the frontal and temporal bones and there was active bleeding from the fracture line, with fresh blood oozing from the gap (suggestive of active intracranial bleed). There was bleeding from the torn middle meningeal vessels that were controlled with coagulation and gel foam. Bleeding from the bone margin was controlled with bone wax. Post-operatively the patient recovered and did well.

DISCUSSION

Acute subdural hematoma can be confused with extradural hematoma on CT scan as it can be lentiform.^{1,2,3} In the same way, rapidly accumulating extradural hematoma can be crescentic in shape as in the present case.² Correct pre-operative recognition of these lesions will help in surgical planning as extradural hematoma needs limited exposure; however, an acute subdural hematoma will need a large craniotomy and may also need duroplasty.

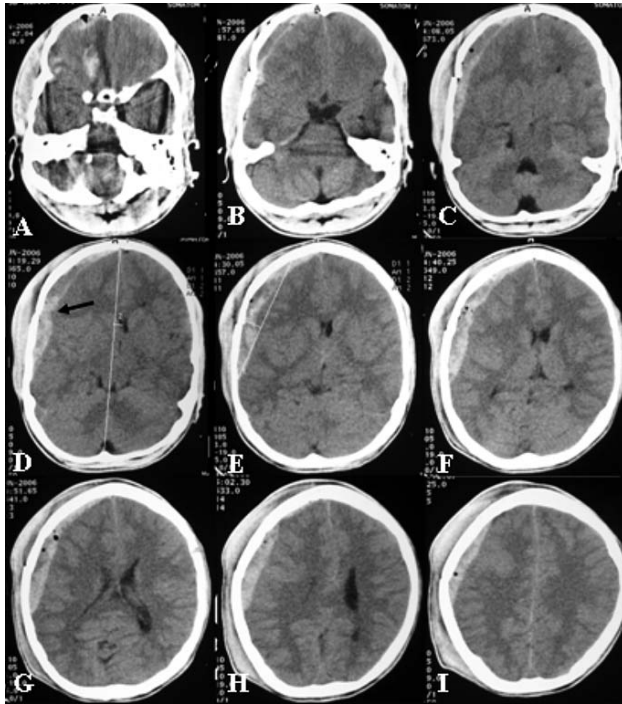


Figure 1. CT scan showing extensive hyperdense crescentic shaped hyperdense collection with areas of hypodensity along the right fronto-temporo-parietal convexity. Note that in panel A the lesion is biconvex with a speck of pneumocephalus, and in panel D the lesion appears separated at the suture line (black arrow). There is associated mass effect and midline shift, although the underlying parenchyma is normal with buckling effect.

Presence of fracture lines in the vicinity of the clot, presence of pneumocephalus in the clot, at places biconvex in shape, features suggesting that the clot is separated by sutures lines, and buckling of gray matter and absence of underlying brain injury on CT scan are suggestive of extradural hematoma in this case. However, diagnostic uncertainty as to whether it is acute subdural hematoma or extradural hematoma should not delay surgical management as delay in management can be fatal.¹

This case illustrates that while interpreting a CT scan one should carefully consider all the features to make a correct diagnosis.

REFERENCES

1. Kato K, Watanabe O, Ozawa Y. Abrupt exacerbation of acute subdural hematoma mimicking benign acute epidural hematoma on computed tomography--case report. *Neurol Med Chir (Tokyo)*. 1999; **39**(1):33-5.

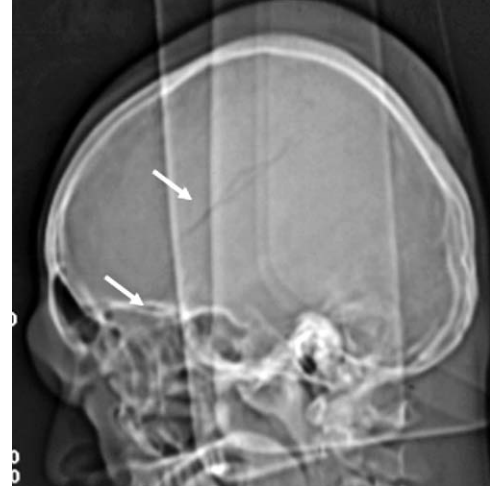

Figure 2. CT scan tomogram showing linear fracture of temporal and parietal bones (arrows)

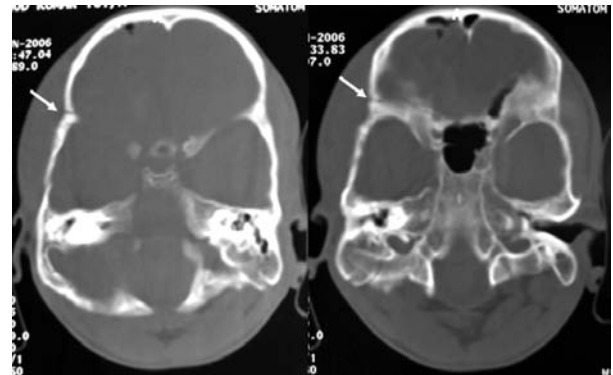


Figure 3. Fracture line extending into the sphenoid bone (arrows)

2. Miyagi Y, Morioka T, Kimura Y, Fukui M. Calcified convexity dura mater and acute epidural hematoma mimicking calcified chronic subdural hematoma. *Neuroradiology*. 1995; **37**(7):551-2.
3. Hurvitz SA, Stone LR, Keenan MA, Waters RL. Acute subdural hematoma mimicking an epidural hematoma on a CT scan. *Brain Inj*. 1989; **3**(1):63-5.